

# **The Possible Therapeutic Effect of Adipose Derived Mesenchymal Stem Cells and N-Acetyl cysteine on Bleomycin Induced Lung Fibrosis in Adult Male Albino Rats: Histological and Immuno-histochemical Study.**

Wafaa M. Abdalla, Omayma K. Helal , Sherifa A. Morsy, Nessrine E. Ahmed.  
Department of Histology and Cell Biology, Faculty of Medicine, Benha University

## **Abstract**

**Background:** Pulmonary fibrosis (PF) is a chronic fibrotic lung disease. Lung parenchyma and architecture is destroyed, compliance is lost, and gas exchange is compromised in this debilitating condition that leads to respiratory failure. NAC is a precursor of L-cysteine that results in glutathione elevation biosynthesis. It acts directly as a scavenger of free radicals, especially oxygen radicals. **This study aimed to** evaluate the possible therapeutic effect of Adipose derived mesenchymal stem cells and N-acetylcysteine (NAC) on induced lung fibrosis in adult male albino rats. **Methods:** Ten rats were used to isolated adipose-derived stem cells and sixty rats were randomly divided into five groups. Group I (control group: 20 rats), Group II (affected group:10 rats), Group III (Adipose stem cell group: 10 rats), Group IV (N-acetylcysteine group:10 rats) and Group V (Adipose stem cell + NAC group: 10 rats). Specimens taken and histological studies, immunohistochemical and morphometric study were performed. **Results:** Group II showed markedly thickened inter-alveolar septa with extensive cellular infiltration and many collapsed alveoli. There was massive lymphocytic infiltration around bronchiolar wall. There was a significant decrease ( $P < 0.01$ ) in collagen fibers accumulation in group III, IV and V compared with group II. There was a significant increase ( $P > 0.01$ ) in Ki67 expression in group III, IV & V compared to group I. **Conclusion:** This work concluded that each of N-acetylcysteine and Adipose-Derived Stem Cells can ameliorate bleomycin induced lung toxicity, but their co-administration can give better results.

The use of adipose tissue- derived stem cells with N-acetylcysteine showed marked reduction in the Bleomycin toxicity and significant improvement of bleomycin induced lung fibrosis. **Keywords:** Bleomycin; N-Acetyl cysteine; Adipose-derived Stem Cells; Picrosirius red stain; ASMA and Ki-67.

## **Introduction**

Bleomycin is an antibiotic complex of several glycopeptides derived from *Streptomyces verticillus*. The cytotoxic action of bleomycin has been attributed to DNA scission and fragmentation with inhibition of usual DNA repair mechanisms. RNA and protein synthesis seem to be inhibited as well. Bleomycin is rapidly cleared from the blood and concentrated in the liver, lungs, spleen, kidneys, and epithelial tissue. Approximately

80% is excreted in the urine within 24 hours. Bleomycin is cell phase specific, having its major effects on cells in the G2 and M phases of the cell cycle (1).

Mesenchymal stromal cells (MSCs) have become one of the most studied cellular therapeutic products by both academia and industry due to their regenerative potential and Immunomodulatory properties. MSC shareholders are unified under one common goal to use MSCs as a therapeutic modality to improve the quality of life for those suffering from a malady (2).

Adipose tissue-derived stem cells (ADSCs) are mesenchymal cells with the capacity for self-renewal and multipotential differentiation. This multipotentiality allows them to become adipocytes, chondrocytes, cells and, in, adipose tissue-derived cells, play a key role in reconstructive or tissue engineering medicine as they have already proven effective in developing new treatments. Stem cells and adipose tissue-derived cells, play a key role in reconstructive or tissue engineering medicine as they can be used to develop new treatments (3).

N-acetyl cysteine (NAC), as a nutritional supplement, is a greatly applied antioxidant in vivo and in vitro. NAC is a precursor of L-cysteine that results in glutathione elevation biosynthesis. It acts directly as a scavenger of free radicals, especially oxygen radicals. NAC is a powerful antioxidant. It is also recommended as a potential treatment option for different disorders resulted from generation of free oxygen radicals. Additionally, it is a protected and mucolytic drug that mellows tenacious mucous discharges. It has been used for treatment of various diseases in a direct action or in a combination with some other medications (4).

This study was conducted to assess the possible protective effect of the anti-oxidant drug NAC and ADSCs in a rat model of bleomycin -induced lung fibrosis by histological and immunohistochemical methods.

### **Materials and methods:**

#### **Drugs and chemicals**

##### **Bleomycin**

It was purchased in a white powder (Sigma Chemical Co., St. Louis, MO, USA). The powder was stored at  $-20^{\circ}\text{C}$ . It was given as single endotracheal injection of freshly prepared bleomycin (2.5 U/kg, dissolved in 0.25 ml of 0.9 NAACL) for each rat (5).

##### **N-Acetylcysteine**

It comes from the amino acid L-cysteine. Amino acids are the building blocks of proteins (6). N-acetyl cysteine has many uses as medicine, (2R)-2-acetylamino-3-sulfanypropanoic acid (Sigma Chemical Co., St. Louis, MO, USA, 138061). The dose of N-acetylcysteine was 3 mmol/kg (5).

##### **Adipose tissue derived MSCs**

They were prepared in stem cell unit, central lab, Cairo university according to the method of a study (7). Isolation and culture of adipose tissue derived mesenchymal stem cells: rats were anesthetized by ketamine (intraperitoneal injection, 100 mg/kg) and xylazine (intraperitoneal injection, 7 mg/kg,) (7). Rats were injected with an intravenous single dose of  $1 \times 10^6$  cell/kg (16).

#### **Animals and Diet:**

This study was done in January 2021 on 70 healthy adult male albino rats weighing (150–200) grams, aging (6-8ws) were obtained from the animal house, Moshtohor Faculty of Veterinary Medicine, Benha University, and received balanced diet with free access to water. All animal procedures were performed according to approved protocols and in accordance with the recommendations for the proper care and use of laboratory animals. They were kept under observation for one week before the beginning of the experiment to acclimatize. The animal experimental protocol was approved by Institutional Animal Care Committee (Ms.29.4.2019).

#### **Experimental design:**

70 adult male albino rats were randomly divided as follows: Ten rats were used to isolate the bone marrow mesenchymal stem cells.

The rats (60) were divided into five groups. Rats were divided into five groups.

**Group I** (control group: 20 rats) were subdivided randomly into 4 subgroups as follow: subgroup Ia (n=5): rats had been received no treatment.

subgroup Ib (n=5): each rat had been received 0.25 ml of 0.9 Nacl (solvent of bleomycin) endotracheally by transoral route.

subgroup Ic (n=5): each rat had been received 1ml of distilled water orally.

subgroup Id (n=5): each rat had been received 1ml of phosphate buffer saline (solvent of mesenchymal stem cells) via rat tail vein.

**Group II** (Bleomycin group; n=10), each rat had been received bleomycin endotracheally by transoral route in a single dose of 2.5 u/kg dissolved in 0.25 ml of 0.9 Nacl (5).

**Group III** (Adipose stem cell group; n=10), rats had been treated by bleomycin as group II then, 2 weeks after induction of lung fibrosis, each rat had been received a single intravenous injection (via rat tail vein) of adipose stem cell in a dose of ( $1 \times 10^6$  cell/kg) (7).

**Group Iv** (N-acetylcysteine group; n=10), rats had been treated by bleomycin as group II, then after 2 weeks (after induction of lung fibrosis) each rat had been received a single oral dose (by gastric tube) of NAC (3mmol/kg) freshly dissolved in 1 ml distilled water.

**Group v** (Adipose stem cell + NAC group; n=10), rats had been treated by bleomycin as group II then 2 weeks (after induction of lung fibrosis) each rat had been received adipose stem cell and NAC in doses like group III and IV.

#### **Sample preparation:**

The lung from the rats will be taken and fixed in 10% buffered formalin, embedded in pure paraffin wax and then mounted into blocks and left at 4 °C until the time of use. The paraffin blocks will be sectioned using the microtome at a thickness of 5 mm and mounted on clean glass slides and then left in the oven at 40 °C for drying.

#### **Preparation of adipose tissue derived MSCs:**

They were prepared in stem cell unit, central lab, Cairo university. Rats were anesthetized by ketamine (intraperitoneal injection, 100 mg/kg) and xylazine (intraperitoneal injection, 7 mg/kg.) (7). The area between the shoulders on the back was shaved and disinfected. A 5 cm incision was made on the skin, and 1 g of subcutaneous adipose tissue was collected and then, the area was sutured, and the postsurgical region was disinfected. Tissues were washed 3 times with phosphate buffered saline (PBS; GIBCO cat. no. 18912-014) containing 1% penicillin and streptomycin (Sigma cat. no. P-4687 and S-1277) to remove the blood cells. The tissue samples were chopped with a scalpel in small pieces and passage and were counted using a hemocytometer. They were resuspended in frozen solution including 10% dimethyl sulfoxide (MP Bio cat. no. 196055) and 90% FBS, at a density of  $2 \times 10^6$  viable cells/ml and were aliquoted into sterile plastic cryovials that were labeled with freezing serial number, and the date. The vials were kept at -20°C for 60 min and then they were transferred to -70°C for 24 h and were digested in 0.2% collagenase Type II at 37°C on a shaker for 40min (8).

#### **Histological and Immunohistochemical Studies**

Paraffin sections of thickness (5 µm very thick), mounted on glass slides for H&E stain to examine histological changes in various groups and picrosirius red staining for demonstration of collagen fibers deposition. Other sections were mounted on +ve charged slides for immunohistochemical staining (9).

Immunohistochemical staining for detection of alpha smooth muscle actin and KI 67. The primary antibody used was the rabbit polyclonal antibody against ASMA and ki 67 antigen for detection them.(Lab Vision Corporation, Neomarkers Laboratories, Westinghouse, Thurmont, California, USA, A11390). Paraffin sections were deparaffinized and hydrated. After blocking the endogenous activity of peroxidase using 10% hydrogen peroxide, the sections were incubated with primary antibodies. Then, after washing with phosphate buffer, the secondary antibody was applied (biotinylated goat anti rabbit). The slides were incubated with labeled avidin–biotin peroxidase, which binds to the biotin on the secondary antibody. The site of antibody binding was visualized

after adding (diaminobenzidine) chromogen, which is converted into a brown precipitate by peroxidase. Sections were counterstained with Meyer's hematoxylin. As a negative control, the primary antibody was replaced with phosphate-buffered saline (PBS). Site of the reaction was brownish color of nuclei in ki 67 and brownish color of cytoplasm in ASMA (10).Tonsil was used as a positive control for ki 67.Positive reaction appeared as brown nuclear coloration and Small intestine used as a positive control for ASMA. Positive reaction appeared as brown cytoplasmic coloration.

### **Morphometric study**

The mean area percentage of collagen fibers accumulation and ASMA and KI-67 immunostaining were quantified in five images from five non-overlapping fields of each slide at magnification 400. Rats using Image-Pro Plus program version 6.0 (Media Cybernetics Inc., Bethesda, Maryland, USA).

### **Statistical analysis**

All the data collected from the experiment was recorded and analyzed using IBM SPSS Statistics software for Windows, Version 20 (IBM Corp., Armonk, NY, USA). One-way analysis of variance (ANOVA) with Post Hoc LSD test was used to compare differences among the groups of morphometric results. In each test, the data was expressed as the mean (M) value, standard deviation (SD) and differences were considered to be significant at  $P < 0.01$ .

### **Results**

#### **BMMSCs characterization and tracking:**

MSCs were identified in culture by inverted microscope as spindle shaped cells (Figure 1A). MSCs labelled with PKH26 fluorescent dye were detected in lung tissues as strong red fluorescence (Figure 1B).

#### **H & E Stain results:**

Examination of all subgroups of the group I (control group) showed similar histological architecture. Therefore, results of subgroup Ia were used to represent this group. Group I (control group); lung sections from group I showed lung consists of terminal bronchioles which is lined by low cuboidal epithelium. The wall of a respiratory bronchioles is lined by squamous epithelium. Alveolar ducts appeared elongate air spaces with almost no walls. An alveolar sac is composed of clusters of alveoli. Alveoli are thin-walled, sac-like structures lined by simple squamous epithelium. The alveolar septum consists of capillaries and minimal connective tissue. The alveoli are separated from one another by thin alveolar walls (interalveolar septa). (Figure 2A).

Group II (Bleomycin group): lung sections from group II showed markedly thickened inter-alveolar septa with extensive cellular infiltration and alveoli were collapsed. And there is massive lymphocytic infiltration around bronchiolar wall was noticed (Figure 2B). Group III (Adipose stem cell group): lung sections from group III showed Marked

amelioration of lung architecture was seen, where most of the alveoli appeared patent with thin inter-alveolar septa but there is Focal areas of limited thickening of inter-alveolar septa were still noticed. Also, there is decrease in inflammatory infiltrations around bronchioles (Figure 2C).

Group IV (N-acetylcysteine group): lung sections from group IV showed slight improvement of alveoli but still there is thickened inter alveolar septa and there is still inflammatory infiltrations. And slight decrease in inflammatory infiltrations around bronchioles (Figure 2D). Group v (Adipose stem cell + NAC group): lung section from group v showed almost normal alveoli and patency of most of alveoli, thin in interalveolar septa nearly normal alveoli. Almost normal appearance of bronchioles was also observed (Figure 2E).

#### **Picosirius red staining results:**

Group I (control group) showed minimal Collagen deposition by picosirius red staining (Figure 3A). Group II (Bleomycin group) showed markedly Collagen deposition by picosirius red staining (Figure 3B). Group III (Adipose stem cell): showed mild Collagen deposition by picosirius red staining (Figure 3C). Group IV (N-acetylcysteine group): showed moderate Collagen deposition detected by picosirius red staining (Figure 3D). Group V (Adipose stem cell + NAC group) showed minimal Collagen deposition by picosirius red staining (Figure 3E).

#### **Alpha smooth muscle actin results:**

Group I (control group) showed lung tissue with minimal reaction for alpha smooth muscle actin (Figure 4A). Group II (Bleomycin group) showed lung tissue with markedly positive cytoplasmic reaction for alpha smooth muscle actin (Figure 4B). Group III (Adipose stem cell group) showed lung tissue with mild positive cytoplasmic reaction for alpha smooth muscle actin (Figure 4C).

Group IV (N-acetylcysteine group) showed lung tissue with moderate positive cytoplasmic immunostaining reaction for alpha smooth muscle actin (Figure 4D). Group V (Adipose stem cell and NAC group) showed lung tissue with minimal positive cytoplasmic immunostaining reaction for alpha smooth muscle actin (Figure 4E).

#### **KI 67 staining results:**

Group I (control group) showed lung tissue with minimal reaction for KI67 (Figure 5A). Group II (Bleomycin group) showed lung tissue with negative reaction for KI67 (Figure 5B). Group III (Adipose stem cell group) showed lung tissue with moderate positive reaction for KI67 (Figure 5C).

Group IV (N-acetylcysteine group) showed lung tissue with mild positive immunostaining reaction for KI67 (Figure 5D). Group V (Adipose stem cell and NAC group) showed lung tissue with markedly positive reaction for KI-67 (Figure 5E).

#### **Morphometric & Statistical analysis:**

The mean area % of collagen fibers accumulation, ASMA and of Ki67 expression for all groups were represented in Tables 1. There was a significant decrease ( $P < 0.01$ ) in collagen fibers accumulation in group III, IV and V compared with group II. There was a significant increase ( $P > 0.01$ ) in Ki67 expression in group III, IV & V compared to group I. Table 1 and Figure 6

## **Discussion**

About 5 million people are affected globally by Pulmonary fibrosis. The disease newly occurs in about 12 per 100,000 people per year (11). Males are affected more often than females (12).

lung tissues of Bleomycin exposed rat group showed markedly thickened inter-alveolar septa with extensive cellular infiltration and alveoli were collapsed. And there is massive lymphocytic infiltration around bronchiolar wall with significant increase ( $P < 0.01$ ) in collagen fibers deposition and ASMA compared with group III, IV, V. These results agreed with (13-19) who recorded that most mice had multifocal or diffuse changes consisting of some combination of thickened alveolar septa, intra-alveolar fibrosis with myofibroblasts within the lumen, occasional foci of dense fibrosis, increased alveolar macrophages, and focal dilatation of respiratory bronchioles and alveolar ducts. There were slight increases in the number of alveolar macrophages and increased cellularity of alveolar septa. In the more severely affected animals, the changes were diffuse and included intra- alveolar fibrosis, focally dense fibrosis, often subpleural, and epithelial hyperplasia in alveolar ducts. Vascular margination and tissue infiltration of neutrophils and macrophages, and increased numbers of perivascular and peribronchiolar lymphocytes were also seen. The main histological damages in BLM-treated mice were alveolar septal destruction.

As regards use of ASCs, results of this study showed marked amelioration of lung architecture, where most of the alveoli appeared patent with thin inter-alveolar septa but there is Focal areas of limited thickening of inter-alveolar septa were still noticed. Also, there is decrease in inflammatory infiltrations around bronchioles. with significant decrease ( $P < 0.01$ ) in collagen fibers deposition and ASMA compared with group II and with ki 67 there is a significant increase ( $P > 0.01$ ) compared with group I. These results were nearly similar to (20, 21) who observed that ASC therapy decreased hyperplasia of cuboidal-shape Club cells (Clara cells) and alveolar epithelial cells (AECs), septal thickening, alveoli enlargement, infiltration of inflammatory cells and extensive fibrosis.

Use of NAC, results of this study showed slight improvement of alveoli but still there is thickened inter alveolar septa and there is still inflammatory infiltrations and slight decrease in inflammatory infiltrations around bronchioles with significant decrease ( $P < 0.01$ ) in collagen fibers deposition and ASMA compared with group II. With a significant increase ( $P > 0.01$ ) in ki 67 compared with group I. The present results were in line with a study (22) investigated that there were less fibroblastic foci, widening alveolar septa and decreased inflammatory cell infiltration. A study (23) found in animals treated with NAC, the severity of alveolitis was lower. The extent of fibrotic lesions and inflammation was reduced in animals treated with NAC.

A study (24) stated that NAC inhibited several profibrotic mechanisms such as the amounts of hydroxyproline, collagen, fibrosis, several cytokines, inflammatory cells and mucus secretory cells. A study (25) observed an alleviation of emphysema in all NAC groups.

As regards use of ASCs and NAC, results of this study showed almost normal alveoli and patency of most of alveoli, thin interalveolar septa and nearly normal alveoli. Almost normal appearance of bronchioles was also observed with significant decrease ( $P < 0.01$ ) in collagen fibers deposition and ASMA compared with group II. with a significant increase ( $P > 0.01$ ) in ki 67 compared with group I. These results matched with a study (26) which stated that the single local administration of MSCs with a reduced number can ensure the therapeutic outcome when the recipient has been conditioned with NAC. The combination therapy of MSC and NAC had superior therapeutic efficacy to that of NAC or MSC monotherapy. Also, a study (27) found that the combination of antioxidant enzyme over expression in MSCs with host NAC treatment significantly improved MSC survival with enhanced circulatory and functional recovery.

### **Conclusion**

The use of adipose tissue- derived stem cells with N- acetylcysteine showed marked reduction in the Bleomycin toxicity and significant improvement of bleomycin induced histological changes of the lung, detected by light microscopic examination. While the use of N-acetylcysteine alone showed mild improvement of Bleomycin induced histological changes on the lung, respectively. So, adipose tissue-derived stem cells with N-acetylcysteine have beneficial effect in Bleomycin induced toxicity as a potent therapeutic agent.

### **Sources of funding**

This research did not receive any specific grant from funding agencies in the public, commercial, or not-for-profit sectors.

### **Author contribution**

Authors contributed equally in the study.

### **Conflicts of interest**

No conflicts of interest

### **References**

1. Murray V, Chen JK, Chung LH. The Interaction of the Metallo-Glycopeptide Anti-Tumour Drug Bleomycin with DNA. *Int J Mol Sci.* 2018;19.
2. Wright A, Arthaud-Day ML, Weiss ML. Therapeutic Use of Mesenchymal Stromal Cells: The Need for Inclusive Characterization Guidelines to Accommodate All Tissue Sources and Species. *Front Cell Dev Biol.* 2021;9:632717.



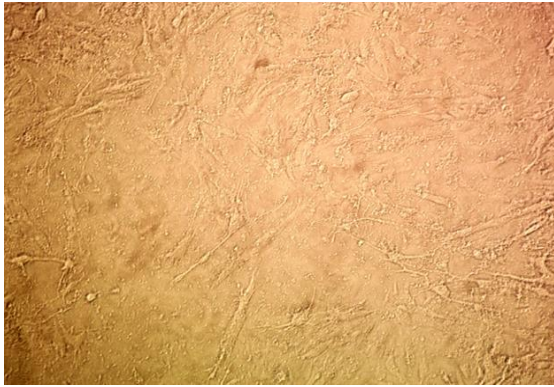
3. Miana VV, González EAP. Adipose tissue stem cells in regenerative medicine. *Ecancermedicalscience*. 2018;12:822.
4. Mokhtari V, Afsharian P, Shahhoseini M, Kalantar SM, Moini A. A Review on Various Uses of N-Acetyl Cysteine. *Cell J*. 2017;19:11-7.
5. Cortijo J, Cerdá-Nicolás M, Serrano A, Bioque G, Estrela JM, Santangelo F, et al. Attenuation by oral N-acetylcysteine of bleomycin-induced lung injury in rats. *Eur Respir J*. 2001;17:1228-35.
6. Dominari A, Hathaway Iii D, Kapasi A, Paul T, Makkar SS, Castaneda V, et al. Bottom-up analysis of emergent properties of N-acetylcysteine as an adjuvant therapy for COVID-19. *World J Virol*. 2021;10:34-52.
7. Mehrabani D, Hassanshahi MA, Tamadon A, Zare S, Keshavarz S, Rahmanifar F, et al. Adipose tissue-derived mesenchymal stem cells repair germinal cells of seminiferous tubules of busulfan-induced azoospermic rats. *J Hum Reprod Sci*. 2015;8:103-10.
8. Rochefort GY, Vaudin P, Bonnet N, Pages JC, Domenech J, Charbord P, et al. Influence of hypoxia on the domiciliation of mesenchymal stem cells after infusion into rats: possibilities of targeting pulmonary artery remodeling via cells therapies? *Respir Res*. 2005;6:125.
9. Bancroft JD, Layton C. The hematoxylin and eosin. *Bancroft's theory and practice of histological techniques*. 2012;7:173-86.
10. Seys LJ, Verhamme FM, Schinwald A, Hammad H, Cunoosamy DM, Bantsimba-Malanda C, et al. Role of B Cell-Activating Factor in Chronic Obstructive Pulmonary Disease. *Am J Respir Crit Care Med*. 2015;192:706-18.
11. Udwadia ZF, Koul PA, Richeldi L. Post-COVID lung fibrosis: The tsunami that will follow the earthquake. *Lung India*. 2021;38:S41-s7.
12. Latoche JD, Ufelle AC, Fazzi F, Ganguly K, Leikauf GD, Fattman CL. Secreted Phosphoprotein 1 and Sex-Specific Differences in Silica-Induced Pulmonary Fibrosis in Mice. *Environ Health Perspect*. 2016;124:1199-207.
13. Chaudhary NI, Schnapp A, Park JE. Pharmacologic differentiation of inflammation and fibrosis in the rat bleomycin model. *Am J Respir Crit Care Med*. 2006;173:769-76.
14. Moeller A, Ask K, Warburton D, Gauldie J, Kolb M. The bleomycin animal model: a useful tool to investigate treatment options for idiopathic pulmonary fibrosis? *Int J Biochem Cell Biol*. 2008;40:362-82.
15. Cho YJ, Yi CO, Jeon BT, Jeong YY, Kang GM, Lee JE, et al. Curcumin attenuates radiation-induced inflammation and fibrosis in rat lungs. *Korean J Physiol Pharmacol*. 2013;17:267-74.
16. Felix RG, Bovolato ALC, Cotrim OS, Leão PDS, Batah SS, Golim MA, et al. Adipose-derived stem cells and adipose-derived stem cell-conditioned medium modulate in situ imbalance between collagen I- and collagen V-mediated IL-17 immune response recovering bleomycin pulmonary fibrosis. *Histol Histopathol*. 2020;35:289-301.
17. Cores J, Hensley MT, Kinlaw K, Rikard SM, Dinh PU, Paudel D, et al. Safety and Efficacy of Allogeneic Lung Spheroid Cells in a Mismatched Rat Model of Pulmonary Fibrosis. *Stem Cells Transl Med*. 2017;6:1905-16.
18. Dinh PC, Paudel D, Brochu H, Popowski KD, Gracieux MC, Cores J, et al. Inhalation of lung spheroid cell secretome and exosomes promotes lung repair in pulmonary fibrosis. *Nat Commun*. 2020;11:1064.

19. Tong B, Fu L, Hu B, Zhang ZC, Tan ZX, Li SR, et al. Tauroursodeoxycholic acid alleviates pulmonary endoplasmic reticulum stress and epithelial-mesenchymal transition in bleomycin-induced lung fibrosis. *BMC Pulm Med.* 2021;21:149.
20. Lee SH, Lee EJ, Lee SY, Kim JH, Shim JJ, Shin C, et al. The effect of adipose stem cell therapy on pulmonary fibrosis induced by repetitive intratracheal bleomycin in mice. *Exp Lung Res.* 2014;40:117-25.
21. Tashiro J, Elliot SJ, Gerth DJ, Xia X, Pereira-Simon S, Choi R, et al. Therapeutic benefits of young, but not old, adipose-derived mesenchymal stem cells in a chronic mouse model of bleomycin-induced pulmonary fibrosis. *Transl Res.* 2015;166:554-67.
22. Li S, Yang X, Li W, Li J, Su X, Chen L, et al. N-acetylcysteine downregulation of lysyl oxidase activity alleviating bleomycin-induced pulmonary fibrosis in rats. *Respiration.* 2012;84:509-17.
23. Zhang H, Yin G, Jiang H, Zhang C. High-dose N-acetylcysteine decreases silica-induced lung fibrosis in the rat. *J Int Med Res.* 2013;41:1179-86.
24. Myllärniemi M, Kaarteenaho R. Pharmacological treatment of idiopathic pulmonary fibrosis - preclinical and clinical studies of pirfenidone, nintedanib, and N-acetylcysteine. *Eur Clin Respir J.* 2015;2.
25. Huang TT, Lai HC, Ko YF, Ojcius DM, Lan YW, Martel J, et al. *Hirsutella sinensis* mycelium attenuates bleomycin-induced pulmonary inflammation and fibrosis in vivo. *Sci Rep.* 2015;5:15282.
26. Shin JH, Ryu CM, Ju H, Yu HY, Song S, Shin DM, et al. Synergistic Effects of N-Acetylcysteine and Mesenchymal Stem Cell in a Lipopolysaccharide-Induced Interstitial Cystitis Rat Model. *Cells.* 2019;9.
27. Zhu Q, Hao H, Xu H, Fichman Y, Cui Y, Yang C, et al. Combination of Antioxidant Enzyme Overexpression and N-Acetylcysteine Treatment Enhances the Survival of Bone Marrow Mesenchymal Stromal Cells in Ischemic Limb in Mice With Type 2 Diabetes. *J Am Heart Assoc.* 2021;10:e023491.

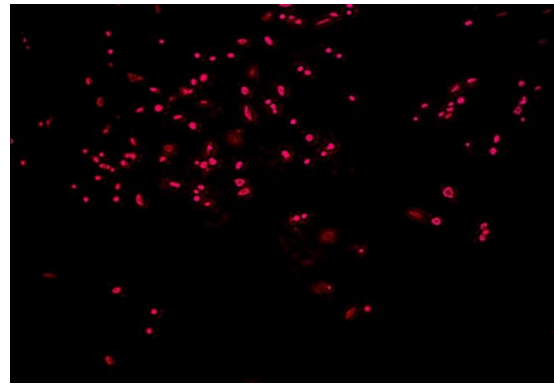
**Table 1: The mean area %, SD of collagen fibers deposition**

	<b>Group I</b>	<b>Group II</b>	<b>Group III</b>	<b>Group IV</b>	<b>Group V</b>
<b>Picrosirius red stain</b>					
<b>Mean area %</b>	1.08%	19.18%	4.23%	7.6%	1.5%
<b>SD</b>	0.1104	0.5945	0.4927	0.4075	0.1864
<b>Significance at P &lt; 0.01</b>	2,3,4	1,3,4,5	1,2,4,5	1,2,3,5	2,3,4
<b>ASMA immunostaining</b>					
<b>Mean area %</b>	0.66%	9.91%	1.96%	3.88%	0.77%
<b>SD</b>	0.0490	0.8674	0.1936	0.1642	0.0769
<b>Significance at P &lt; 0.01</b>	2,3,4	1,3,4,5	1,2,4,5	1,2,3,5	2,3,4
<b>Ki-67 immunostaining</b>					
<b>Mean area %</b>	0.27%	0.00%	1.47%	0.56%	2.44%
<b>SD</b>	0.0560	0	0.3372	0.0834	0.3565
<b>Significance at P &lt; 0.01</b>	2,3,5	1,3,4,5	1,2,4,5	2,3,5	1,2,3,4

1: sig. with group I, 2: sig. with group II, 3: sig. with group III, 4: sig. with group IV, 5: sig. with group V

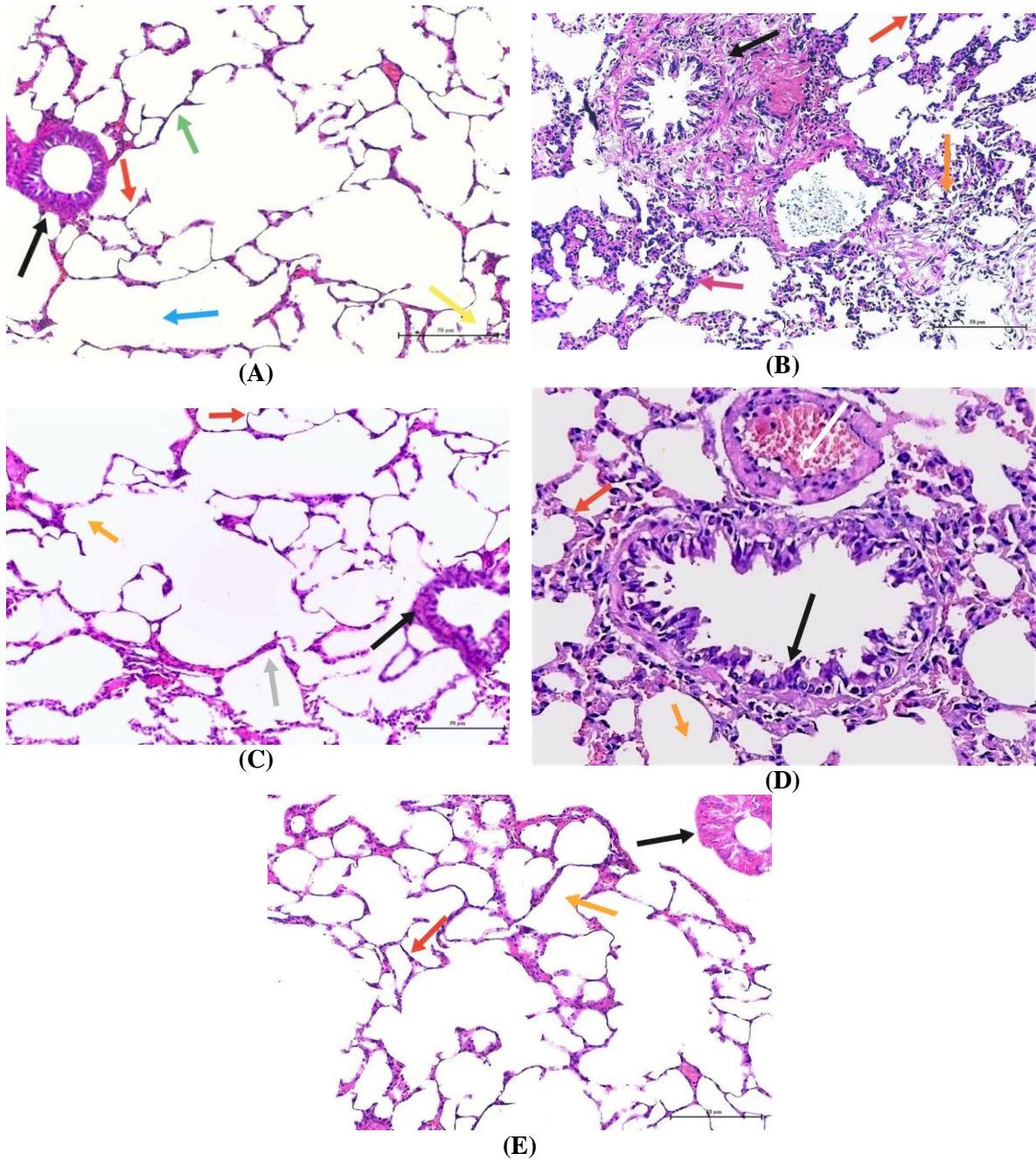


(A)



(B)

**Figure 1: (A) Inverted microscope micrograph from primary culture of MSCs showed spindle shaped cells (X200). (B) A fluorescent microscope photograph showed homing of Adipose derived mesenchymal stem cell labelled with PKH26 dye in lung tissue (X1000).**

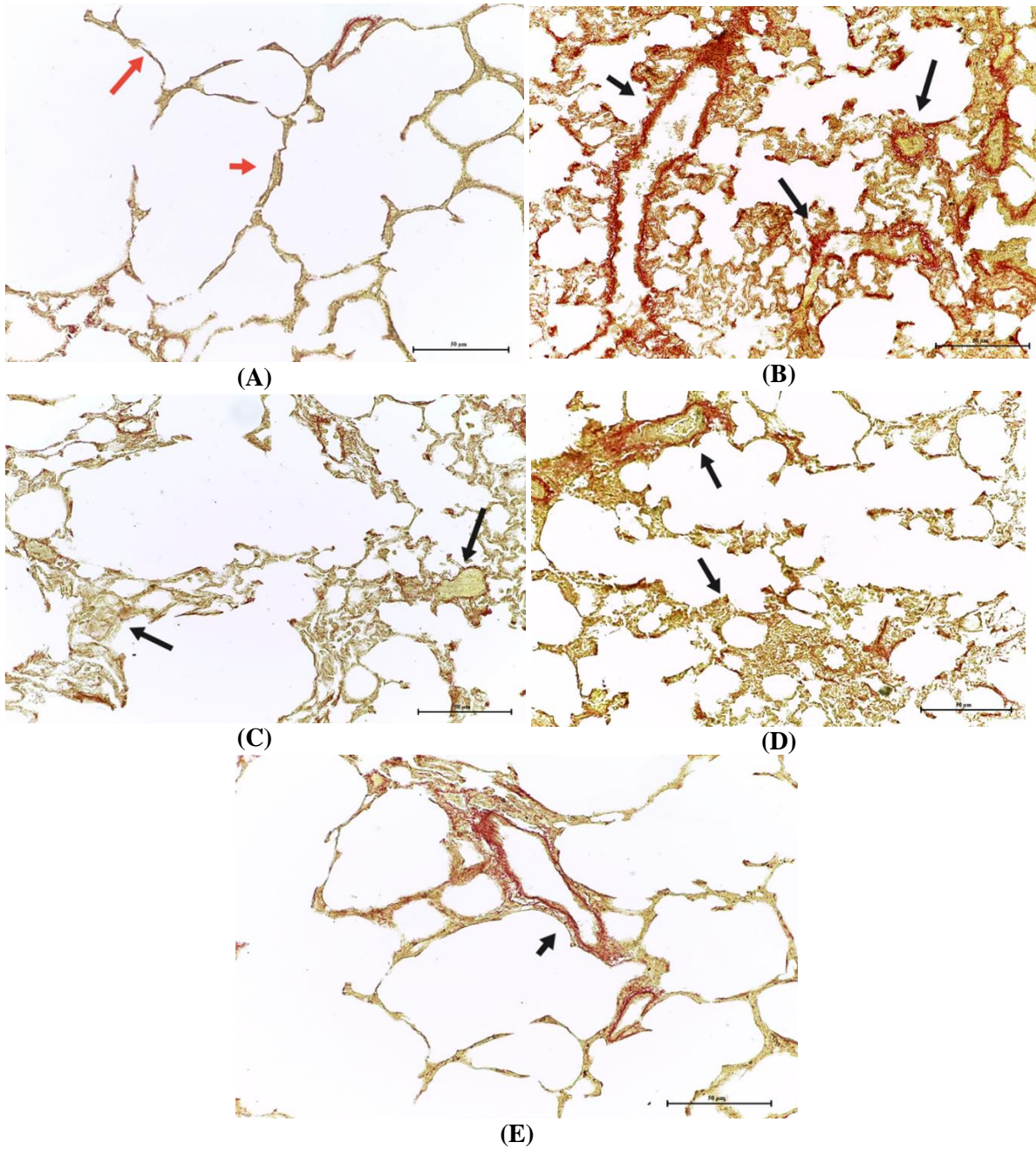


**Figure 2: (A) (group I) showed the lung consists of terminal bronchioles (black arrow), respiratory bronchiole (green arrow), Alveolar ducts (blue arrow), alveolar sac (yellow arrow) and inter alveolar septa (red arrow). (B) (group II) showed markedly thickened inter-alveolar septa (red arrow), there is extensive cellular infiltrations (orange arrow), and alveoli are Collapsed (pink arrow) .Massive lymphocytic infiltration around bronchiolar wall (black arrow). (C) group (III) showed nearly normal lung architecture, most of the alveoli appeared patent(orange arrow) with thin inter-alveolar septa (red arrow) . Focal areas of limited thickening of inter-alveolar septa (grey arrow). There is decrease in inflammatory infiltrations around bronchioles (black arrow),**


**(D) group (IV) showed slight improvement of alveoli (orange arrow) but still there is thickened inter alveolar septa and there is still inflammatory infiltrations (red arrow), there is congested blood vessels (white arrow). Slight decrease in inflammatory infiltrations around bronchioles (black arrow). (E) group (V) showed almost normal alveoli (orange arrow) and patency of most of alveoli, thin interalveolar septa (red arrow), Almost normal appearance of bronchioles was also observed (black arrow) .**

**(H&E X200)**






**Figure 3: (A) (group I) showed minimal Collagen deposition between alveoli (arrows), (B) (group II): showed markedly positive Collagen deposition between alveoli (arrows), (C) (group III) showed mild Collagen deposition between alveoli (arrows), (D) (group IV): showed moderate Collagen deposition between alveoli (arrows), (E) (group V): showed minimal Collagen deposition between alveoli (arrows) (picrosirius red staining X200)**

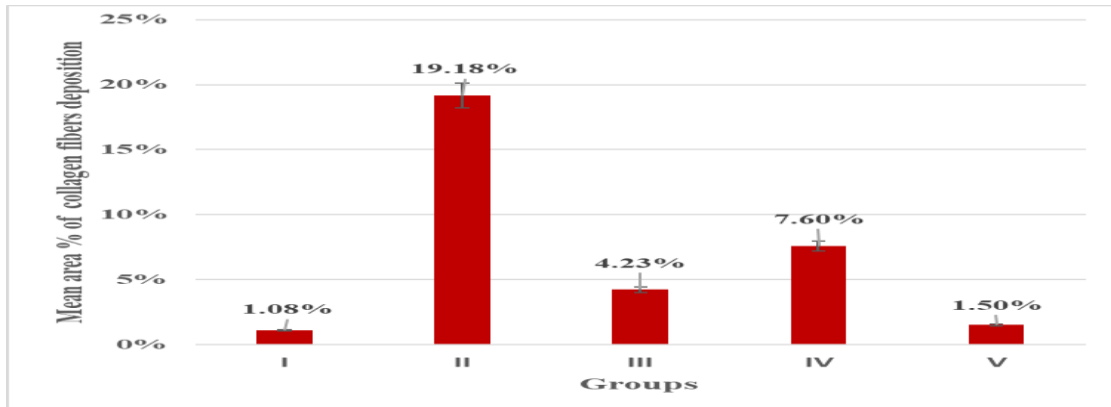


**Figure 4: (A) (group I) showed minimal cytoplasmic reaction in cells lining of alveoli (arrows). (B) (group II): showed markedly positive cytoplasmic reaction in cells lining of alveoli (arrows). (C) (group III): showed mild positive cytoplasmic reaction in cells lining of alveoli (arrows). (D) (group IV): showed moderate positive cytoplasmic reaction in cells lining of alveoli (arrows). (E) (group V): showed minimal positive cytoplasmic reaction in cells lining of (arrows) (ASMA, X200).**

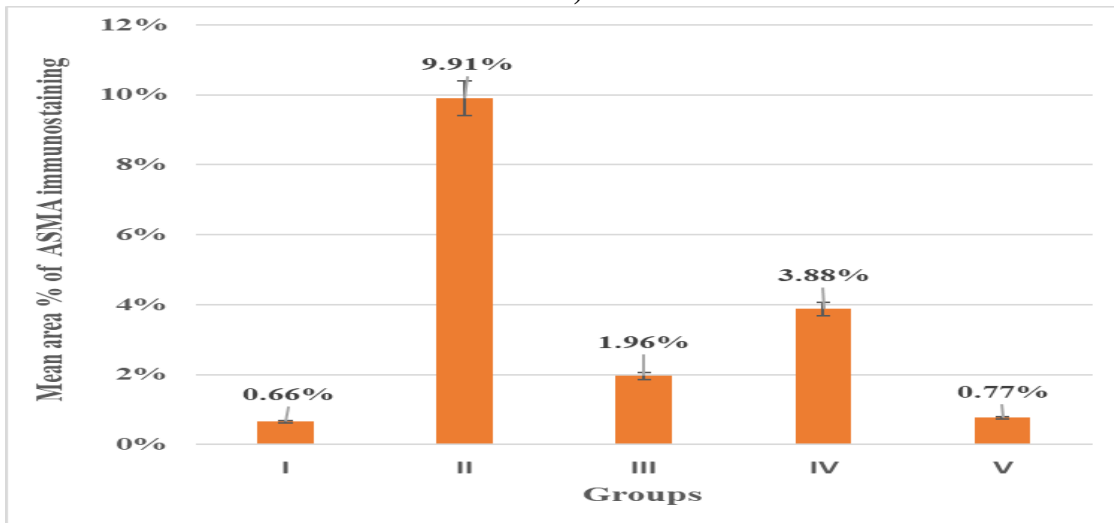




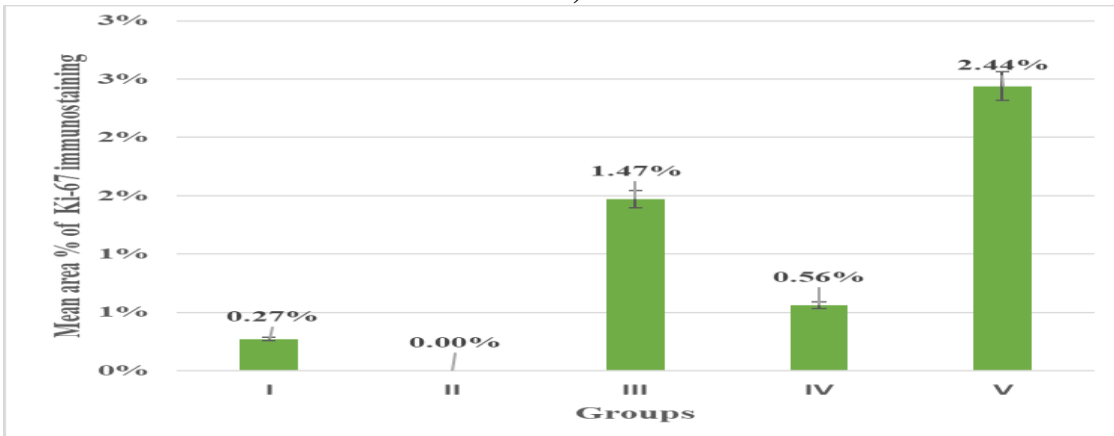
**Figure 5: (A) (group I) with minimal reaction for KI67 (arrows), (B) (group II ) with negative reaction for KI67, (C) (group III) with moderate positive reaction for KI67(arrows), (D) (group IV) with mild positive reaction for KI67( arrows). (E) (group V) with markedly positive reaction for KI-67 (arrows) (Ki, X200).**



A)



B)



C)

**Figure 6: A) Showing the mean area % of collagen fibers deposition in groups I, II, III, IV and V, B) Showing the mean area % of ASMA immunostaining in groups I, II, III, IV and V and C) Showing the mean area % of Ki-67 immunostaining in groups I, II, III, IV and V.**